

A case report of primary psammomatous serous adenocarcinoma of the peritoneum

Purwa R Patil^a, Bhavana M Bharambe^{a*}, Aditi H Mahure^a, Madhumita D Kurdukar^a, Amruta A Patil^a and Kalpana A Deshpande^a

^aDepartment of Pathology, Grant Medical College, Mumbai, India

*Corresponding author, email: bhavanab.136@gmail.com

Extraovarian peritoneal serous papillary carcinoma is an uncommon malignant tumour characterised by peritoneal involvement with ascites, which is similar to ovarian serous papillary carcinoma histologically. Our case involved only the surface and superficial cortex of the ovaries, with peritoneal involvement, as described in the literature.

Keywords: extraovarian peritoneal serous papillary carcinoma, EPSPC, psammomatous carcinoma, serous carcinoma peritoneum

Introduction

Extraovarian peritoneal serous papillary carcinoma (EPSPC) is a rare malignant tumour which presents as peritoneal carcinomatosis with no evidence of the primary site of origin. It was first described by Swerdlow in 1959 as "mesothelioma of the pelvic peritoneum".¹ Since then, it has been reported under various names, such as primary peritoneal serous carcinoma, serous surface papillary carcinoma, papillary serous carcinoma of the peritoneum and extraovarian peritoneal serous papillary carcinoma. EPSPC is considered to arise from the secondary Müllerian system, and is histologically indistinguishable from ovarian serous papillary carcinoma.² It is tenth as common as its ovarian counterparts.

Case study

A 65-year-old woman presented with complaints of distension of and pain in the abdomen of three months' duration. She was postmenopausal and known to be hypertensive and on treatment. The patient's family history was non-significant. On clinical examination, she had gross ascitis with no obvious palpable mass as per an abdominal and vaginal examination.

On investigation, her biochemical and haematological profile was normal. In view of the abdominal distension, an ultrasonography of the abdomen was performed, which confirmed the ascites. In addition, mildly dilated bowel loops were shown, with a maximum diameter of 3.2 cm. The uterus was of a normal size. Ascitic fluid tapping was performed. Metastatic adenocarcinoma was reported following the cytological examination. As the previously performed ultrasonography was inconclusive with regard to the primary tumour site, computed tomography (CT) of the abdomen was conducted, which revealed mild omental thickening, with multiple hyperdense deposits in the mesentery, omentum and pouch of Douglas, suggestive of metastatic deposits, together with the ascites. The uterus and both ovaries were reported to be normal.

On further investigation, the serum CA 125 and CA 15.3 levels were markedly raised, while the carcinoembryonic antigen levels were normal.

As there were extensive deposits in the mesentery and peritoneum on radio imaging, as per the protocols of the institute, a decision

was taken to provide preoperative chemotherapy, with the target of achieving optimum cytoreduction prior to debulking surgery. The patient was given three cycles of chemotherapy (paclitaxel plus carboplatin) on a daycare basis. CT of the abdomen was repeated, revealing a significant reduction in free fluid and in the size of the mesenteric deposits, when compared to the previous CT report. The patient was advised of debulking surgery, and posted for the same after two months. After one month, follow-up ultrasonography showed a complex, irregular mass of 1.5 × 2 cm in the left adnexa. The left ovary was not visualised. The right ovary and uterus were normal. The omentum was echogenic in places. The radiologist concluded that the left adnexal mass could be an ovarian neoplasm or metastatic deposit.

Due consideration was given to the last imaging report, and the patient was posted for surgery. Intraoperatively, the surgeon found an atrophic uterus with normal-sized ovaries. However, the external surface of both the ovaries was rough. The omentum had thickened. Bilateral salpingo-oophorectomy was performed and sent for frozen section examination so that the ovaries could be assessed to rule out the primary site of origin. On frozen section examination, serous type adenocarcinoma with multiple psammoma bodies were seen in the superficial cortical stroma of the ovary. An extraovarian site of origin was considered by the surgeon: probably the peritoneum. In addition, a total hysterectomy and omentectomy were performed, with resection of the right and left pelvic nodes, right paracolic tissue and peritoneal tissue near the splenic flexure.

On gross examination, the uterus and cervix were unremarkable. The external surface of both the ovaries (which were received separately) was rough and was gritty to cut (Figure 1).

The omentum showed four, solid, ill-circumscribed greyish-white areas. The largest was 7 × 4 × 2 cm, and the smallest 3 × 2 × 2 cm. There was a single greyish-white area of 0.1 cm in diameter on the peritoneum (Figure 1).

On microscopical examination, multiple tumour foci, confined to the surface epithelium and underlying superficial cortical stroma, were observed in both ovaries (Figure 2).

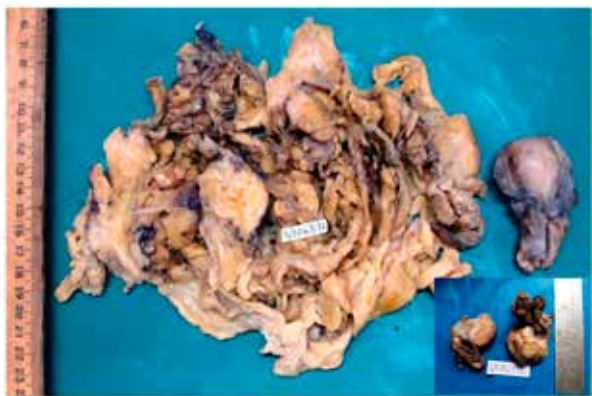


Figure 1: Multifocal omental and peritoneal thickening, with an uninvolved uterus. Inset: The ovaries were of normal size with no grossly identifiable tumour

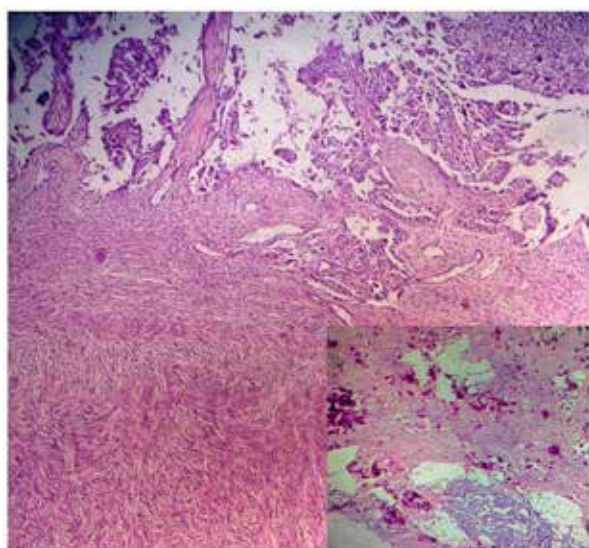


Figure 2: Surface involvement of the ovary by carcinoma, with peritoneal deposits. Inset: Dense psammoma bodies with malignant deposits are evident

All of the foci were less than 0.1 cm in diameter, and comprised neoplastic papillae with a fibroblastic core and sheets of tumour cells. The individual tumour cells were cuboidal, with a moderate amount of eosinophilic to clear cytoplasm, and hyperchromatic and pleomorphic nuclei. Numerous psammoma bodies were also seen within and around the tumour cells at places in which the tumour morphology was obscured. Similar tumour foci were seen within the serosal aspect of the Fallopian tubes, omentum and peritoneum (Figure 2).

A diagnosis of EPSPC was made based on the criteria of the Gynaecology Oncology Group.¹

Discussion

EPSPC is a rare, malignant, epithelial tumour which commonly occurs in postmenopausal women with a median age of 56–62 years. However, cases have been reported in children and a male patient. Clinically, a patient with EPSPC usually presents with abdominal pain, ascites, and clinical symptoms and signs similar to women experiencing stage IV ovarian carcinoma. However, a radiological investigation and intraoperative findings

in these women show diffuse peritoneal deposits with normal-sized ovaries, which mimic diffuse malignant mesothelioma or diffuse peritoneal carcinomatosis with unknown primary origin.

The patient had similar presenting complaints and prechemotherapy imaging results in this case. However, the post-chemotherapy imaging results and intraoperative findings led to suspicion of a tumour of ovarian origin.

EPSPC is histologically similar to ovarian serous carcinoma, owing to the secondary Müllerian origin of the tumour. However, various theories have been proposed as to the origin of this tumour. Mesothelial or coelomic epithelial origin has been cited in older studies, while newer developments point towards the possibility of the origin being the fimbrial end of the Fallopian tube.³ Evidence of BRCA1⁴ and p53 mutations has also been reported in the literature.² The Gynecologic Oncology Group¹ have proposed criteria for the diagnosis of EPSPC. They are divided into low and high grade histologically. Low-grade peritoneal serous carcinomas are very rare and are similar to ovarian serous borderline tumours, but with demonstrable lymphovascular and visceral invasion. High-grade peritoneal serous carcinomas resemble typical ovarian serous carcinoma.

Thus, the criteria for the diagnosis of EPSPC are the following:

- Both of the ovaries are either normal in size, or enlarged by a benign process. However, the bulk of the tumour is in the peritoneum.
- Microscopical examination of the ovaries reveals one of the following: no tumour; a tumour that is confined to the surface epithelium, with no evidence of cortical invasion; a tumour involving the ovarian surface and the underlying cortical stroma, but which is less than 5 mm × 5 mm in diameter; and lastly a tumour that is less than 5 mm × 5 mm within the ovarian substance, and with or without surface involvement.
- The histological and cytological characteristics of the tumour are predominantly serous, and they are similar or identical to those of ovarian serous papillary adenocarcinoma of any grade.
- In cases in which an oophorectomy had been performed before the diagnosis of EPSPC, the following must have been performed: a pathology report to document the absence of carcinoma in the specimen, with a review of all of the slides if the oophorectomy was performed within five years of the diagnosis of EPSPC; and a pathology report of the specimen is required if the oophorectomy was performed more than five years' ago.

Immunohistochemistry is useful in differentiating EPSPC from malignant mesothelioma. However, not much is achieved by differentiating it from ovarian carcinoma of comparable grade and stage. Thus, the significance of the previously mentioned proposed criteria is stressed. It has been demonstrated in the literature that immunostaining with β -catenin, epithelial cadherin, wnt5a, epidermal growth factor receptor, vascular endothelial growth factor, vimentin, Ki67 and p53 has been shown to help.² The significantly higher expression of oestrogen and progesterone receptors within primary ovarian serous papillary carcinoma has been reported in a few studies only in which primary ovarian serous papillary carcinomas were compared.⁵

EPSPC has been found to have a similar or worse prognosis than that of stage III/IV ovarian carcinomas.

Conclusion

This case was included here because patients rarely present with EPSPC. It was also included to emphasise the role played by the pathologist in elucidating the site of origin of cancer in order to ensure a positive impact on the patient's treatment and prognosis.

References

1. Swerdlow M. Mesothelioma of the pelvic peritoneum resembling papillary cystadenocarcinoma of the ovary: case report. *Am J Obstet Gynecol.* 1959;77:197–200.
2. Hou T, Liang D, He J, et al. Primary peritoneal serous carcinoma: a clinicopathological and immunohistochemical study of six cases. *Int J Clin Exp Pathol.* 2012;5(8):762–9
3. Seidman JD, Zhao P, Yemelyanova A. "Primary peritoneal" high-grade serous carcinoma is very likely metastatic from serous tubal intraepithelial carcinoma: assessing the new paradigm of ovarian and pelvic serous carcinogenesis and its implications for screening for ovarian cancer. *Gynecol Oncol.* 2011;120:470–3.
4. Bhanvadia VM, Parmar JK, Madan YG, et al. Primary peritoneal serous carcinoma: a rare case and palliative approach. *Indian J Palliat Care.* 2014;20:157–9.
5. Liu Q, Lin JX, Shi QL, et al. Primary peritoneal serous papillary carcinoma: a clinical and pathological study. *Pathol Oncol Res.* 2011;17:713–9.

Received: 22-08-2015 Accepted: 02-11-2015